

**Case Report**

# Laugier-Hunziker syndrome: a case report and literature review

Amber Kiyani<sup>a\*</sup>, Zahra Moeen<sup>b</sup>, Atiqa Mariam<sup>c</sup>

<sup>a</sup> Department of Oral Diagnosis and Medicine, Riphah International University, 7th Avenue, G-7/4, Islamabad, Pakistan.

<sup>b</sup> Department of Oral Pathology, Riphah International University, 7th Avenue, G-7/4, Islamabad, Pakistan.

<sup>c</sup> Smiles of Youth Project, 60/C, Satellite Town, Rawalpindi, Pakistan.

\* Corresponding author: akiyani@gmail.com

Submitted: 14/10/2016. Accepted: 16/11/2016. Published online: 16/11/2016.

**Abstract** Laugier-Hunziker syndrome (LHS) is an acquired disorder characterized by pigmentation of oral tissues and nails. We present a case of LHS in an 89-year-old male that was seen at the college of dentistry when the patient presented for routine dental care.

**Keywords:** Laugier-Hunziker syndrome, oral melanosis, oral pigmentation.

## Introduction

Laugier-Hunziker syndrome (LHS) is an acquired mucocutaneous disorder that is characterized by benign, permanent pigmentation of the oral mucosa, and less frequently, nails (Nayak *et al.*, 2012). The oral pigmentation begins spontaneously as tiny brown-black macules that progressively increase in size (Veraldi *et al.*, 1991). The nails when involved demonstrate longitudinal or patchy areas of pigmentation. Involvement of skin, sclera, oesophagus, genital and perianal region has also been reported (Rangwala *et al.*, 2010; Wang *et al.*, 2012). The pigmentation arises from excess deposition of melanin in the epithelium, but the exact aetiology of this condition is currently unknown (Wang *et al.*, 2012). We present a single case of LHS in a previously undiagnosed elderly patient.

## Case report

An 89-year-old edentulous, Pakistani male was seen in the student clinics for new dentures. During the initial intraoral assessment, the student noted diffuse areas of macular black pigmentation on buccal, labial and alveolar mucosae (Fig. 1-3).

According to the patient, the pigmentation had been present for about 30 years. It first began as tiny black spots that gradually increased in size over a period of time. Involvement of nails, skin and other mucosal sites was absent. Since the pigmentation was completely asymptomatic, the patient had never actively sought medical attention. The patient was in good health with a medical history negative for any systemic illnesses or medications. He also denied use of any tobacco products.

Following consent, an incisional biopsy was performed. The microscopic presentation of the tissue specimen was unremarkable except for the accumulation of melanin in the basal cell layer of the epithelium. Macrophages with deposits of melanin were also noted in the superficial connective tissue (Fig. 4).

The patient was then referred to a physician for a complete systemic evaluation. He underwent a series of investigations including serological testing, endoscopies and an abdominal ultrasound. No systemic causes of oral pigmentation were identified. Based on the clinical presentation, histopathologic appearance and absence of any systemic causes of pigmentation, a diagnosis of LHS was

made. Since the patient did not express any aesthetic concerns, no treatment was provided.

### Differential diagnosis

In order to make a diagnosis of LHS, other causes of oral pigmentation need to be ruled out. Considerations in the differential diagnosis may include physiological pigmentation, smoker's melanosis, Peutz-Jegher disease, and Addison's disease.

Physiological pigmentation results from excess melanin deposition in oral tissues of dark-skinned individuals. The colour of the tissues varies from light to dark brown depending on the amount of melanin deposited. While any part of the oral cavity may be involved, anterior gingiva is most commonly affected. It begins in younger patients and is significantly noticeable by the second or third decade of life (Gaeta *et al.*, 2002). In contrast, the pigmentation in LHS patient initiates in the fifth decade of life (Veraldi *et al.*, 1991).

Smoker's melanosis is diffuse brown-black pigmentation of the gingiva, hard palate, and buccal mucosa in heavy cigarette smokers. Rarely, it may also be seen in the laryngeal mucosa. The pigmentation fades away once the patient quits smoking, however, the pigmentation associated with LHS is permanent. A negative history of tobacco use helps eliminating this from the list of possible differential diagnosis (Nayak *et al.*, 2012).

Peutz-Jegher syndrome is a rare, genetic disease that presents as spotty pigmentation in the oral cavity and periorificial regions. This disease is also characterized by the presence of intestinal polyps that undergo malignant transformation. Although the perioral and oral freckling can mimic LHS, the absence of intestinal polyps is sufficient to rule out this condition from the differential diagnosis (Jelsig *et al.*, 2014).

Addison's disease results from immune-mediated destruction of the adrenal gland. Oral pigmentation is often the first sign of adrenocortical insufficiency. Over a period of time gastrointestinal disturbances, hypotension and cutaneous

hyperpigmentation result. While the pigmentation in Addison's disease is diffuse, patients with LHS have normal cortisol levels and no systemic signs and symptoms (Sachdeva *et al.*, 2011).

Other causes of oral pigmentation such as heavy metal exposure, medications, acquired immunodeficiency syndrome, melanoacanthoma, intraoral melanoma, LAMB and LEOPARD syndromes, and post inflammatory melanosis were not relevant considerations in our patient (Rangwala *et al.*, 2010; Sreeja *et al.*, 2015; Barman *et al.*, 2016).

Development of pigmentation in the fifth decade, a negative history of smoking, absence of intestinal polyps and normal cortisol levels supported a diagnosis of LHS in our patient.

### Discussion

LHS was first presented in the literature through a case series in 1970. This case series described 5 patients with a history of progressive macular oral pigmentation. Two of these patients also presented with melanonychia (Laugier and Hunziker 1970). LHS tends to show a female predilection (Nikitakis and Koumaki 2013). Affected patients are usually in their fifth decade of life (Aliagaoglu *et al.*, 2008). Although cases of this pigmentation disorder have been described all over the world, it appears to be more prevalent in European countries (Rangwala *et al.*, 2010).

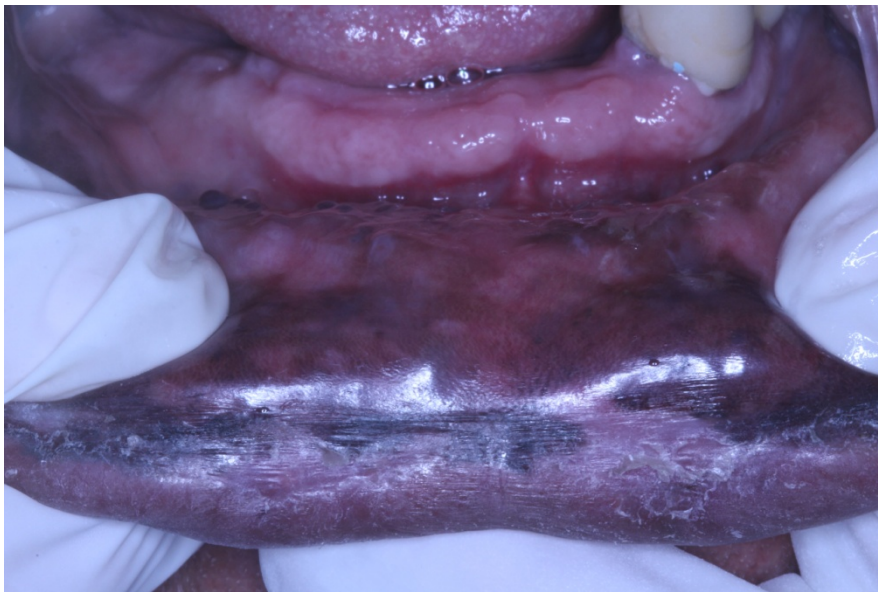The oral pigmentation associated with LHS begins spontaneously as 2 to 5 mm brown-black macules. The pigmentation gradually increases in size resulting in confluence of multiple macules to create larger areas of diffuse pigmentation (Veraldi *et al.*, 1991; Wang *et al.*, 2012). Nail pigmentation is less frequent and is seen in only 60% of affected individuals (Sachdeva *et al.*, 2011). It presents as black longitudinal streaks, or larger homogenous areas on the surface, or generalized involvement of the subungual area (Sachdeva *et al.*, 2011; Wang *et al.*, 2012). Sporadic reports of pigmentation in sclera, skin, oesophagus, genitals and perianal areas in association with LHS had also

been reported (Veraldi *et al.*, 1991; Gerbig and Hunziker, 1996; Yamamoto *et al.*, 1999).

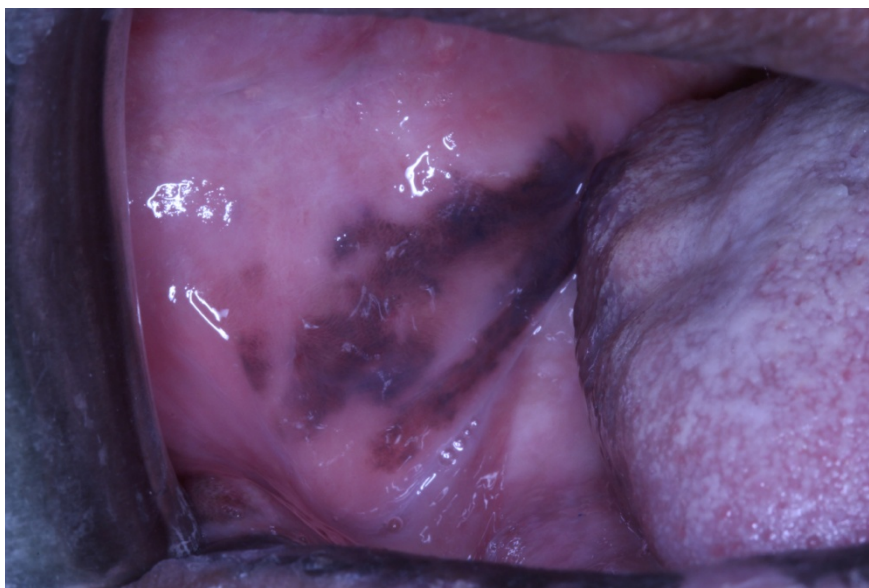The histologic appearance from oral lesions is described as accumulation of melanin in the basal cell layer of the epithelium and in the macrophages in the papillary connective tissue. Because no changes are noted in the number, morphology and the distribution of melanocytes, it is speculated that the pigmentation is solely a result of increased melanocytic activity (Wang *et al.*, 2012; Barman *et al.*, 2016).

LHS is not associated with malignant transformation but the pigmentation may cause esthetic concerns in some patients. Cryotherapy, Q-switched Nd-Yag and alexandrite lasers can be used as possible treatment options in such patients. Resistance to some treatment modalities has also been reported (Ergun *et al.*, 2013).

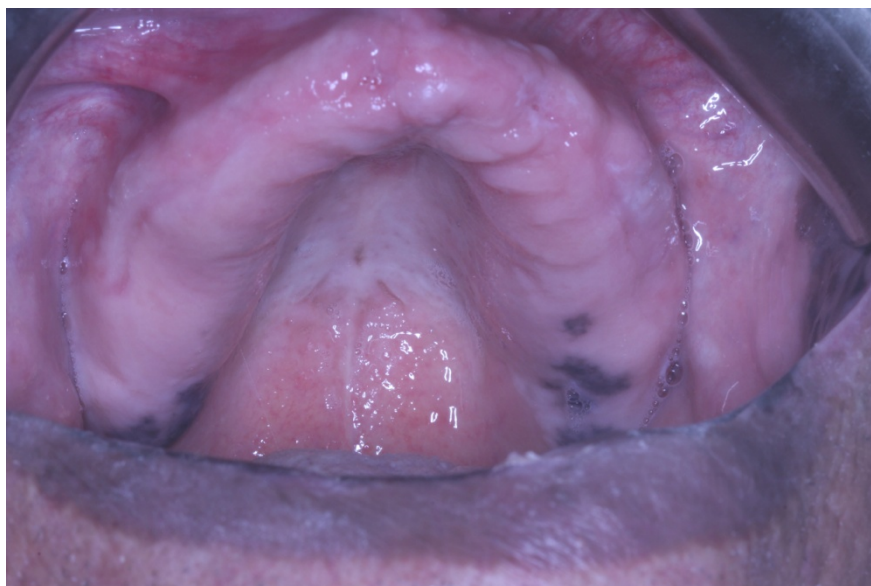Although oral pigmentation is a characteristic feature of LHS, the majority of the dentists are unaware of this entity. Dentists should be familiar with this process so an accurate diagnosis can be made.



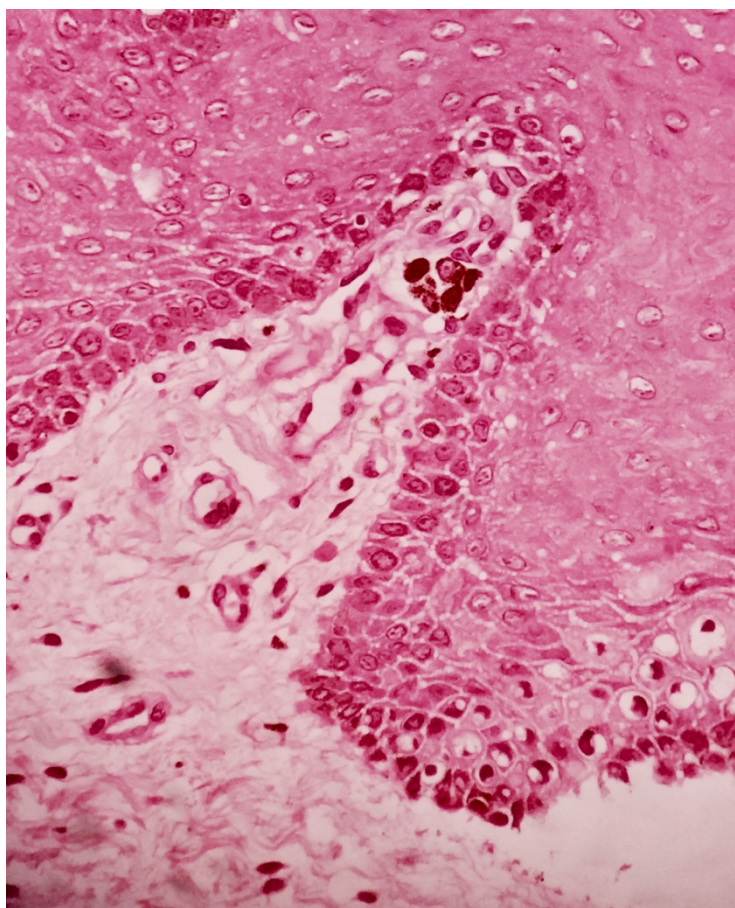
**Fig. 1** Pigmentation of the lower labial mucosa.



**Fig. 2** Bilateral pigmentation of the buccal mucosa.



**Fig. 3** Pigmentation on the maxillary alveolar mucosa.



**Fig. 4** Melanin deposits in the basal cell layer of the epithelium and accumulation of melanin in macrophages in the superficial connective tissue.

## References

- Aliagaoglu C, Yanik ME, Albayrak H, Güvenç SC, Yildirim U (2008). Laugier-Hunziker syndrome: diffuse large hyperpigmentation on atypical localization. *J Dermatol*, **35**(12): 806-807.
- Barman PD, Das A, Mondal AK, Kumar P (2016). Laugier-Hunziker syndrome revisited. *Indian J Dermatol*, **61**(3): 338-339.
- Ergun S, Saruhanoğlu A, Migliari DA, Maden I, Tanyeri H (2013). Refractory pigmentation associated with Laugier-Hunziker syndrome following Er:YAG laser treatment. *Case Rep Dent*, **2013**: 561040.
- Gaeta GM, Satriano RA, Baroni A (2002). Oral pigmented lesions. *Clin Dermatol*, **20**(3): 286-288.
- Gerbig AW, Hunziker T (1996). Idiopathic lenticular mucocutaneous pigmentation or Laugier-Hunziker syndrome with atypical features. *Arch Dermatol*, **132**(7): 844-845.
- Jelsig AM, Qvist N, Brusgaard K, Nielsen CB, Hansen TP, Ousager LB (2014). Hamartomatous polyposis syndromes: a review. *Orphanet J Rare Dis*, **9**: 101.
- Laugier P, Hunziker N (1970). [Essential lenticular melanic pigmentation of the lip and cheek mucosa]. *Arch Belg Dermatol Syphiligr*, **26**(3): 391-399.
- Nayak RS, Kotrashetti VS, Hosmani JV (2012). Laugier-Hunziker syndrome. *J Oral Maxillofac Pathol*, **16**(2): 245-250.
- Nikitakis NG, Koumaki D (2013). Laugier-Hunziker syndrome: case report and review of the literature. *Oral Surg Oral Med Oral Pathol Oral Radiol*, **116**(1): e52-e58.
- Rangwala S, Doherty CB, Katta R (2010). Laugier-Hunziker syndrome: a case report and review of the literature. *Dermatol Online J*, **16**(12): 9.
- Sachdeva S, Sachdeva S, Kapoor P (2011). Laugier-hunziker syndrome: a rare cause of oral and acral pigmentation. *J Cutan Aesthet Surg*, **4**(1): 58-60.
- Sreeja C, Ramakrishnan K, Vijayalakshmi D, Devi M, Aesha I, Vijayabanu B (2015). Oral pigmentation: A review. *J Pharm Bioallied Sci*, **7**(Suppl 2): S403-S408.
- Veraldi S, Cavicchini S, Benelli C, Gasparini G (1991). Laugier-Hunziker syndrome: a clinical, histopathologic, and ultrastructural study of four cases and review of the literature. *J Am Acad Dermatol*, **25**(4): 632-636.
- Wang WM, Wang X, Duan N, Jiang HL, Huang XF (2012). Laugier-Hunziker syndrome: a report of three cases and literature review. *Int J Oral Sci*, **4**(4): 226-230.
- Yamamoto O, Yoshinaga K, Asahi M, Murata I (1999). A Laugier-Hunziker syndrome associated with esophageal melanocytosis. *Dermatology*, **199**(2): 162-164.